


SURVIVORSHIP ANALYSIS OF CAD-CAM TOTAL SHOULDER REPLACEMENT

A Prinja, SK Nayar, W Rudge, A Majed, D Higgs, D Butt, M Falworth

Wrightington Gold Medal Research Meeting

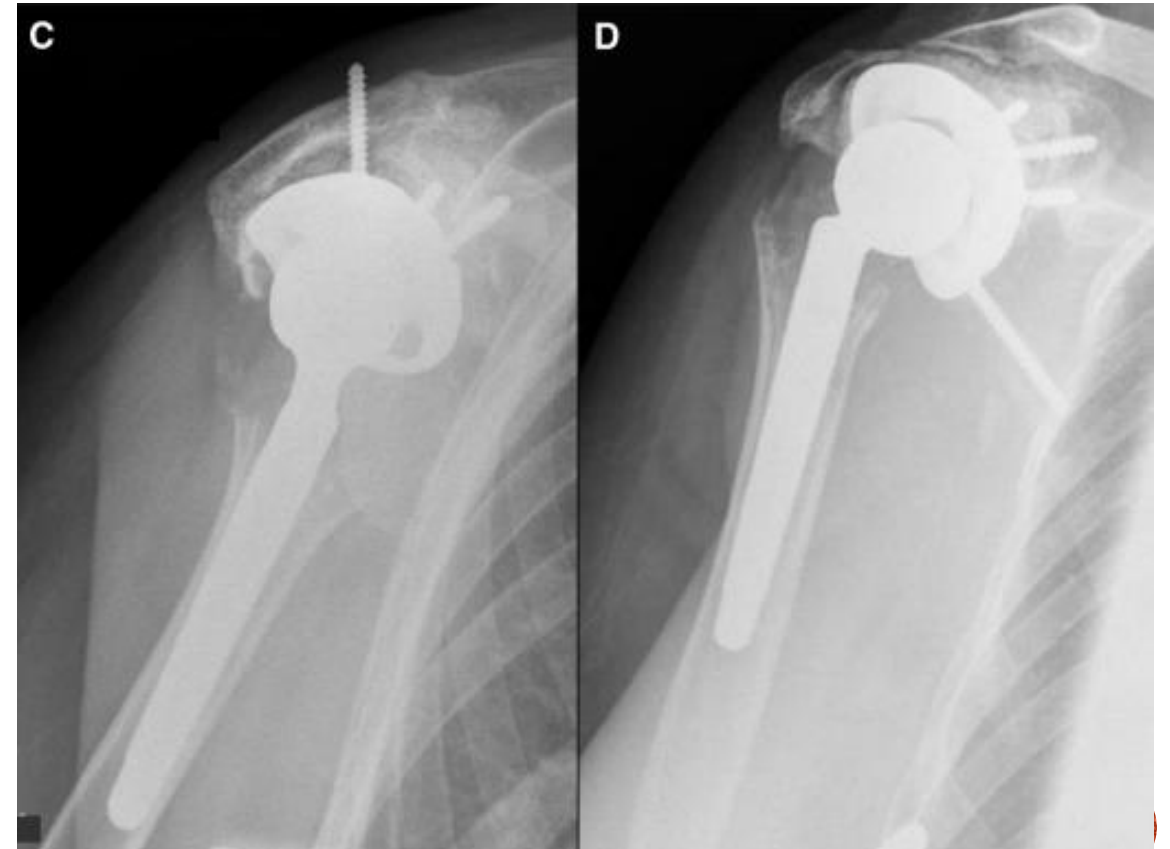
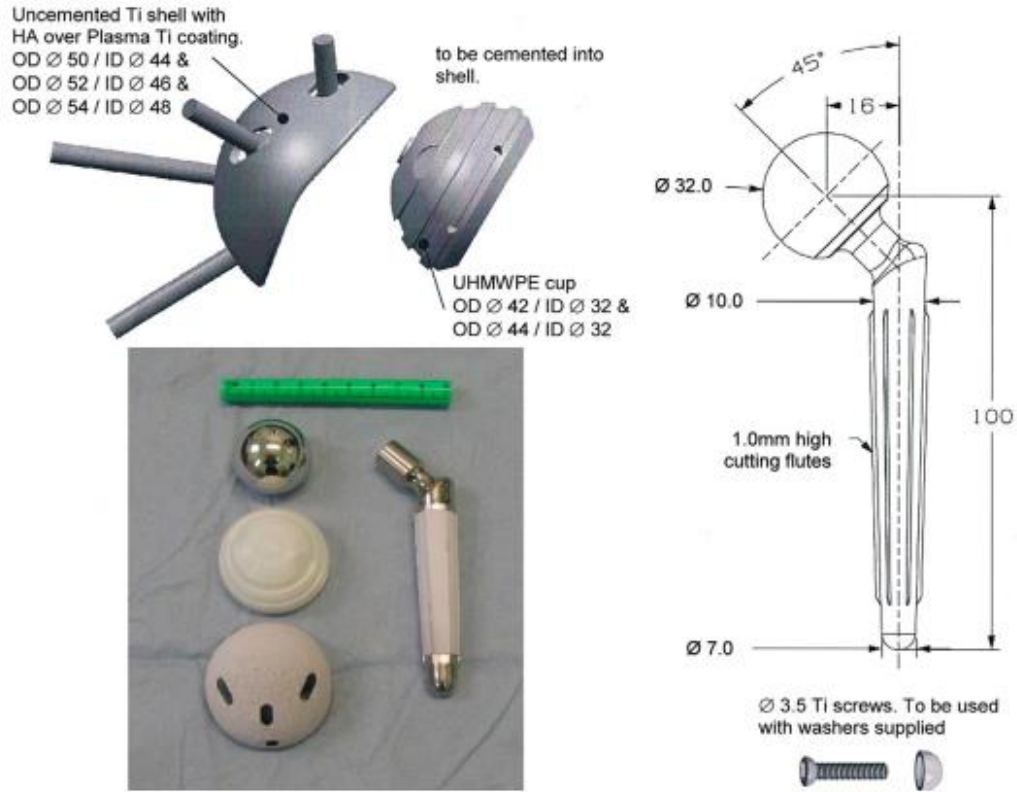
16th July 2020

Shoulder and Elbow Unit, Royal National Orthopaedic Hospital, Stanmore



BACKGROUND & AIM

1. Assess survivorship of the CAD-CAM TSR
2. Assess long-term outcomes including pain, function and patient satisfaction



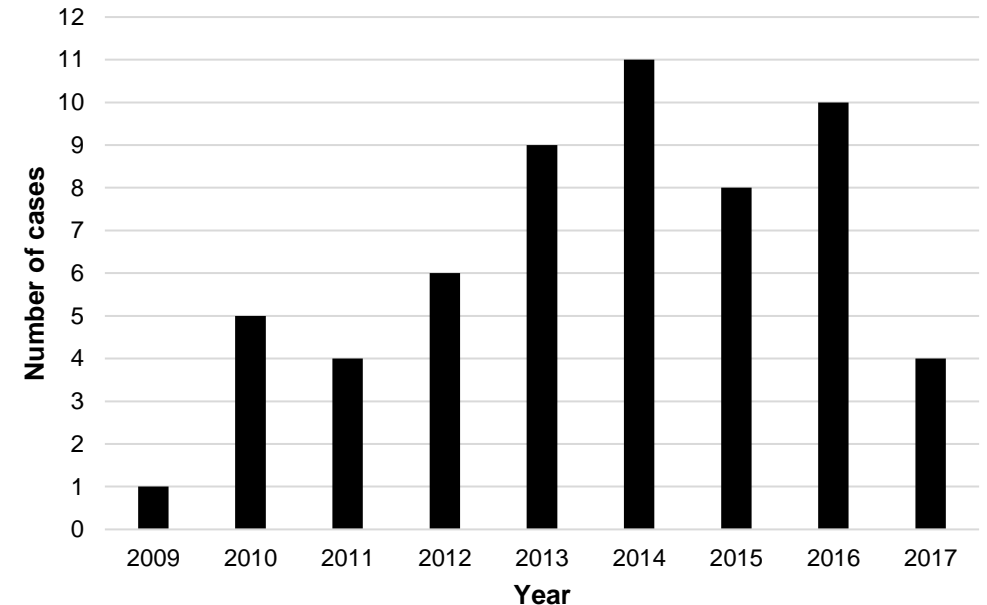
METHODS

- Review of patients that underwent a constrained, anatomic CAD-CAM TSR utilising a glenoid shell between 2009 & 2019
- Data collected on:
 1. Survivorship
 2. Range of movement
 3. Oxford Shoulder Score (OSS, 0 to 48)
 4. Subjective Shoulder Value (SSV, 0 to 100%)
 5. Pain score (0 to 10)
 6. Overall patient satisfaction



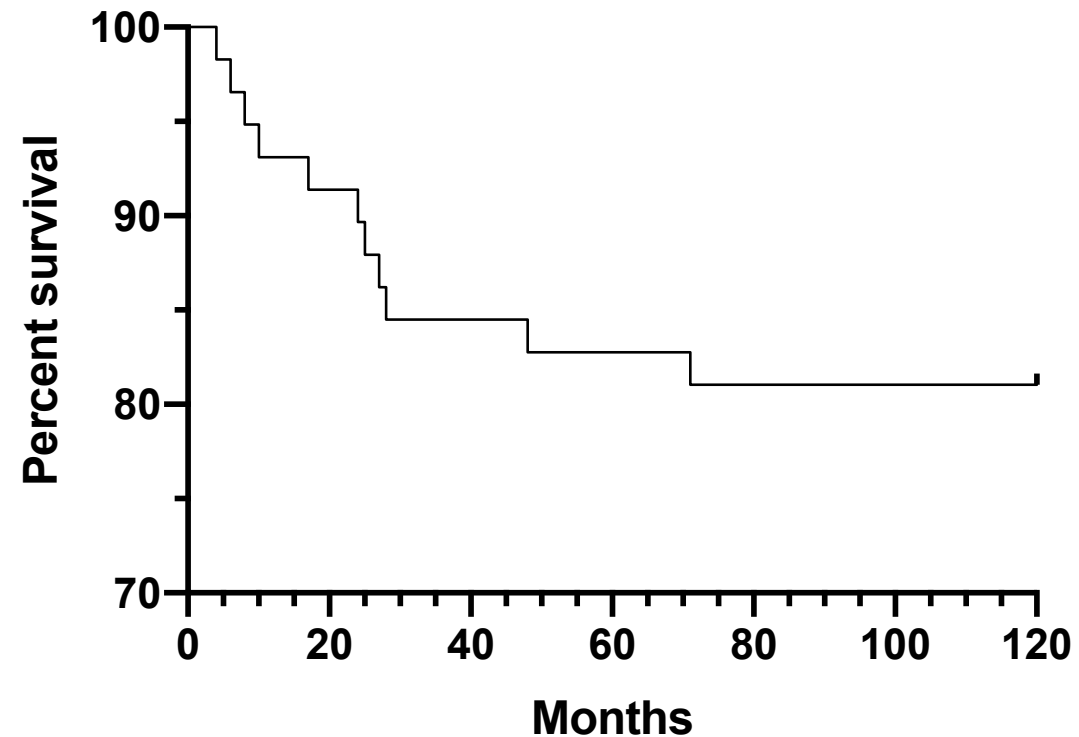
RESULTS - DEMOGRAPHICS

- 58 patients identified
- Mean age at time of operation = 70.8 years (range 48 to 86)
- %F:M = 75.9% (44 patients)
- Indications:
 1. Primary procedure in 16 cases (28%) due to end-stage glenohumeral arthritis with severe glenoid bone loss
 2. Revision procedure in 42 cases (72%)



RESULTS - SURVIVORSHIP

- Reoperation required in 11 patients (19%) with component revision in 10 at a mean time of 24 months
 - 4 for prosthesis loosening
 - 3 for infection
 - 3 for periprosthetic fracture
- 3-year survivorship = 86.2%
- 6-year survivorship = 82.8%



RESULTS – ROM & PROMS

	Pre-operative	Post-operative (latest follow-up)	P value
Active ROM			
Forward elevation, °	45 ± 27	59 ± 29	0.0056
Abduction, °	43 ± 29	55 ± 26	0.034
External rotation, °	8 ± 11	16 ± 14	0.031
PROMS			
OSS (0- to 60-point scale)	15 ± 8	29 ± 9	0.0009
SSV, %	18 ± 16	62 ± 23	<0.0001
Pain score (0 to 10 scale)	8 ± 2	2 ± 2	<0.0001

CONCLUSIONS

- CAD-CAM TSR should be reserved for complex cases with severe glenoid bone loss
- In such instances, CAD-CAM implants offer significant improvements in pain and function with overall positive patient satisfaction

